

HISTOLOGICAL CHANGES INDUCED BY THE ACTION OF ACTARA 25WG INSECTICIDE IN *RANA RIDIBUNDA* PALLAS 1771

PĂUNESCU Alina, PONEPAL Maria Cristina,
DRĂGHICI Octavian, MARINESCU Alexandru Gabriel

Abstract. In the present investigation, we studied the skin of *Rana ridibunda* PALLAS 1771 adult specimens' treated with Actara 25WG in a dose of 0.4 mg/g body weight and keep at 4-6°C respectively at 22-24°C. The toxic was administrated by intraperitoneal injection, 1 injection at 2 days in a scheme for 3 weeks. At the end of experiment we observe some morphological modification in skin in both variants.

Keywords: amphibians, frog, skin, thiamethoxame, Actara 25WG.

Rezumat. Modificări histologice induse de acțiunea insecticidului Actara 25WG la *Rana ridibunda* PALLAS 1771. În prezentul studiu s-a urmărit structura tegumentului la adulți de *Rana ridibunda* PALLAS 1771 tratați cu Actara 25WG în concentrație de 0.4 mg/g greutate corporală și ținută la o temperatură de 4-6°C respectiv 22-24°C. Toxicul a fost administrat prin injecții intraperitoneale, 1 injecție la 2 zile timp de 3 săptămâni. La sfârșitul experimentului s-au observat modificări morfologice ale tegumentului, în ambele variante studiate.

Cuvinte cheie: amfibieni, broaște, tegument, thiamethoxame, Actara 25WG.

INTRODUCTION

Pesticides adversely affect non-target organisms and are widely used in agricultural ecosystems, wherein amphibians, the non-target species, are major components of the wetland biota (GURUSHANKARA et al., 2007). Thus, frogs living in agricultural ecosystems and wetlands are exposed to these pesticides (KAUR & CHEMMA, 1986; LAMBERT, 1997).

The product investigated in our experiments - Actara 25WG (250 mg/l of thiamethoxame) has been used for the protection of crops and vegetables against bed bugs, the Colorado potato beetle, trips, aphides, flea beetles, whiteflies, stink bugs etc. Thiamethoxame is a neonicotinoid insecticides and its chemical name is: {3-[(2-chloro-5-thiazolyl)methyl]tetrahydro-5-methyl-Nnitro-4H-1,3,5-oxadiazin-4-imine}.

These chemical structures are slightly different than the other neonicotinoid insecticides, making it the most water soluble of this family (FISHEL, 2005).

The mode of action is essentially one of cytotoxicity, cell death, both as single cell necrosis and apoptosis, and increased cell replication rates (GREEN et al., 2005). Our goal was to describe the histological changes induced by the action of Actara 25WG in *Rana ridibunda* PALLAS 1771 skin.

MATERIAL AND METHODS

The animals examined in this study were adult of *Rana ridibunda* frogs (male and female) captured in the surrounding areas of the city Pitesti (South Romania). This species was choose because, the amphibians, especially the frogs, are the animals that are best suited for the work in the laboratory.

The animals were kept in laboratory condition in aquaterrarios filled with tap water for five days to test their health and accommodate them for the experiment. The water was changed daily to avoid the accumulation of toxic substances.

The animal used in the experiment were grouped into four experimental lots as it follows: control lot 1 composed of 10 specimens of untreated *Rana ridibunda*, with an average weight of 45g (male and female), maintained in laboratory conditions at a temperature of 4-6°C in containers with tap water which was changed daily; lot 2 consisted of 10 specimens (5 male and 5 female) of *Rana ridibunda*, with an average weight of 43g, maintained under the same conditions as lot 1 (at a temperature of 4-6°C) and treated for 3 weeks with Actara 25WG in concentration of 0.4 mg/g per body weight; control lot 3 with 10 specimens (male and female) of untreated *Rana ridibunda*, with an average weight of 47g, maintained in laboratory conditions at a temperature of 22-24°C in containers with tap water which was changed daily; lot 4 consisted of 10 specimens of *Rana ridibunda* (5 male and 5 female), with an average weight of 50g, maintained under the same conditions as control lot 3 (at a temperature of 22-24°C) and treated for 3 weeks with Actara 25WG in a concentration of 0.4 mg/g per body weight. The administered dosage of insecticide was not lethal as none of the subjects died through the experiment. During the experiment the animals were not fed.

The toxic substance was administered by intraperitoneal injection, one injection at 2 days in a scheme for 3 weeks.

We began sacrificing the animals at the end of treatment by decapitation, under chloroform anesthesia, and skin fragments, approximately 1 cm², were quickly removed. The pieces were fixed in 8% formalin for poikilotherms

and further processed for paraffin wax-embedding using routine protocols. Consecutive 5 µm-thick sections were cut using a rotary microtome (Slee Maintz Cut 5062) and a series of sections were stained with H&E and Sirius red for collagen (JUNCUEIRA et al., 1979).

RESULTS AND DISCUSSIONS

The body of adult amphibians is protected principally by mucus (MADERSON & ALIBARDI, 2000), and thus the body is covered by a largely non-keratinizing epidermis that suffices for aquatic life (MITTAL & BANERJEE, 1980).

Amphibians' epidermis presents some structural particularity; it exhibits a relatively thin hornified surface composed of one or two layers of flattened cells that retain their nuclei. Most functions of the epidermis can be considered protective or defensive (LILLYWIGHT, 2006).

The majority of these functions reside in the stratum corneum, and of these, the protective function of the water permeability barrier is paramount (CHUONG et al., 2002). Skin secretion, which is secreted by the spinal glands of these animals in response to the external impact, contains peptides with diverse activities. These include antibacterial, antiviral, antitumor peptides, as well as peptides with fungicidal activity and neuropeptides (SAMGINA et al., 2008).

The dermis is composed of connective tissue and contains various connective tissue cells, smooth muscle cells, chromatophores, multicellular simple alveolar glands, diffuse blood vessels and nerves.

After 3 weeks of treatment with Actara 25WG in a dose of 0.4 mg/g body weight there were not detected degenerative alterations, but remarkable morphologic modifications. At 4-6°C, the thiamethoxame produced a pronounced hypertrophy of the mucous and granular glands and in addition we registered an intense secretion of the mucous (Figs. 1a, b). Mucous glands were located in the dermis in close proximity to the epidermis (Fig. 1b). The lumina of the granular glands contained elliptical and spherical secretory granules, which were eosinophilic and PAS-negative (Fig. 1b).

We noticed the tendency of epidermis to become thicker and the hornified cells showing picnotic nuclei (Fig. 2).

The epidermis of *Rana ridibunda* treated with Actara 25WG in a dose of 0.4 mg/g body weight and kept at 22-24°C, consisted more layers of cells, which overlay the dermis (Fig. 3a).

To protect the profound structures, the epidermis becomes more stratified. This perturbations of the frogs epidermis could be induced by exposure to pollutants (FENOGLIO et al., 2006), in this case, by the action of Actara 25WG.

The dermis is not very thin and the collagen fibers are more abundant (Fig. 3b).

The skin is also protected and kept moist by the mucus produced by mucous glands (LI et al., 2006). During the experiment we registered an intensive mucous secretion.

Similar research has been carried out by PĂUNESCU et al. (2010), studying the effects of Reldan 40EC on *Rana ridibunda* skin. They found that this insecticide is more toxic at 22-24°C than 4-6°C. The Samurai insecticide determinates similar histological changes in the skin of *Rana ridibunda* (PĂUNESCU et al., 2008).

Taking into account the role of the frog epidermis in ion and water transport (LINDEMANN & VOÛTE 1976), it is likely that the changes we found in morphologic features in epidermis of treated frogs probably affect the barrier role and the transport function of this epithelium (FENOGLIO et al., 2006).

CONCLUSIONS

We conclude that Actara 25WG in a dose of 0.4 mg/g body weight determinates morphologic modifications in the skin of *Rana ridibunda* in both variants (at 4-6° and at 22-24°C). Our results show a higher number of hypertrophied mucous glands and, simultaneous, an intense secretion of mucous.

The epidermis becomes more stratified with hornified cells showing picnotic nuclei. Possibly these processes are consistent with the degree of epidermal cells keratinization. The parameters studied in this investigation could be used as biomarkers of exposure to thiamethoxame.

Thus, the exposure to pesticides and other xenobiotics have been suggested as one possible cause of amphibian population declines.

REFERENCES

- CHUONG C. M., NICKOLOFF B. J., ELIAS P. M., GOLDSMITH L. A., MACHER E., MADERSON P. A., SUNDBERG J. P., TAGAMI H., PLONKA P. M., THESTRUP-PEDERSEN K. 2002. *What is the 'true' function of skin?* Experimental Dermatology. **11**: 159-187.
- FENOGLIO C., GROSSO A., BONCOMPAGNI E., MILANESI G., GANDINI C., BARNI S. 2006. *Morphofunctional Evidence of Changes in Principal and Mitochondria-Rich Cells in the Epidermis of the Frog Rana kl. esculenta Living in a Polluted Habitat*. Archives of Environmental Contamination and Toxicology **51**: 690-702.
- FISHEL F. M. 2005. *Pesticide toxicity profile: neonicotinoid pesticides*. UF/IFAS EDIS Document PI-80. Available at: <http://edis.ifas.ufl.edu/PI117> (accessed April 14, 2010).

- GREEN T., TOGHILL A., LEE R., WAECHTER F., WEBER E., NOAKES J. 2005. *Thiamethoxam Induced Mouse Liver Tumors and Their Relevance to Humans. Part 1: Mode of Action Studies in the Mouse*. Toxicological Sciences **86**(1): 36-47.
- GURUSHANKARA H. P., KRISHNAMURTHY S. V., VASUDEV V. 2007. *Effect of Malathion on Survival, Growth, and Food Consumption of Indian Cricket Frog (*Limnoneustes limncharis*) Tadpoles*. Archives of Environmental Contamination and Toxicology. **52**: 251-256.
- JUNCUEIRA L. C. U., BIGNOLAS G., BRENTANI R. R. 1979. *Picrosirius staining plus polarization microscopy, a specific method for collagen detection in tissue section*. Histochemical Journal. **11**: 447-455.
- KAUR K. & CHEEMA G. 1986. *Acute toxicity of some pesticides to the eggs and larvae of the common carp, *Cyprinus carpio**. Zoology Oriental. **2**: 52-58.
- LAMBERT M. R. K. 1997. *Effect of pesticides on amphibians and reptiles in sub-Saharan Africa*. Reviews Environmental Contamination and Toxicology. **150**: 31-73.
- LI K. W., LEE D. N., HUANG W. T., WENG C. F. 2006. *Temperature and humidity alter prolactin receptor expression in the skin of toad (*Bufo bankorensis* and *Bufo melanostictus*)*. Comparative Biochemistry and Physiology. **145** (A): 509-516.
- LILLYWHITE H. B. 2006. *Water relations of tetrapod integument. Review*. The Journal of Experimental Biology. **209**: 202-226.
- LINDEMAN B. & VOÛTE C. 1976. *Structure and function of the epidermis*. In: Llinas RR, Precht H (eds). Frog neurobiology. Springer Verlag. New York: 169-210.
- PĂUNESCU A., PONEPAL C. M., DRĂGHICI O., MARINESCU AL. G. 2008. *Histologic Modification Induced by the Action of the Insecticide Samurai on the Skin and Liver of *Rana ridibunda**, „A 60-a aniversare a Facultății de Horticultură” și „A 10-a aniversare a specializării de peisagistică”. Seria **B**(51): 666-670.
- PĂUNESCU A., PONEPAL C. M., DRĂGHICI O., MARINESCU AL. G. 2010. *Histological changes induced by the action of the insecticide Reldan 40EC in *Rana ridibunda**. Lucrări Științifice. Seria Horticultură. USAMV Iași. (In press).
- MADERSON P. F. A. & ALIBARDI L. 2000. *The development of the sauropsid integument: A contribution to the problem of the origin and evolution of feathers*. American Zoology. **40**: 513-529.
- MITTAL A. K. & BANERJEE T. K. 1980. *Keratinization versus mucus secretion in fish epidermis*. In The Skin of Vertebrates (ed. R. I. C. Spearman and P. A. Riley). Linnaean Society Symposium Series. London: 1-12.
- SAMGINA T. YU., ARTEMENKO K. A., GORSHKOV V. A., LEBEDEV A. T. 2008. *Bioactive peptides from the skin of ranid frogs: modern approaches to the mass spectrometric de novo sequencing*. Russian Chemical Bulletin, International Edition. **57**(5): 1080-1091.

Păunescu Alina, Ponepal Maria Cristina,
Drăghici Octavian, Marinescu Alexandru Gabriel
University of Pitești, Faculty of Science, Department of Ecology,
2 Targu din Vale Street, 410087 Pitești, Romania,
E-mail: alina_paunescu@yahoo.com

Received: May 3, 2010
Accepted: August 28, 2010

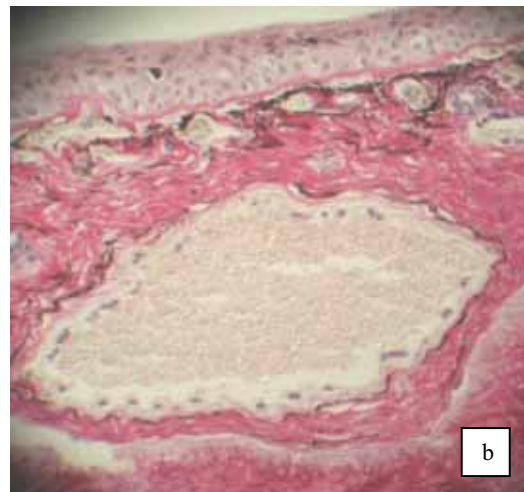
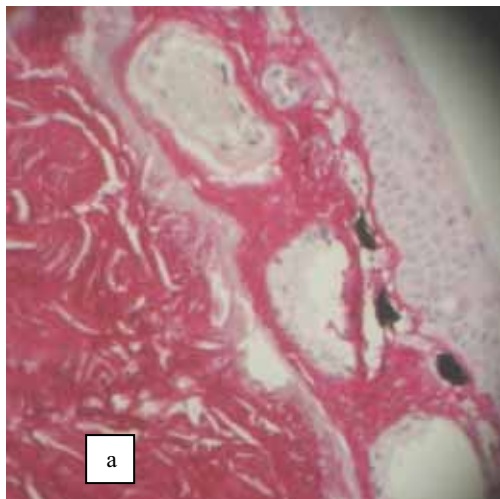


Figure 1. Paraffin-embedded section from the skin of the frog *Rana ridibunda* PALLAS 1771 showing hypertrophy of mucous (a) and granular glands (b). H-Sirius red. 100 \times . (original). / Figura 1. Secțiune prin tegument de *Rana ridibunda* PALLAS, 1771 care indică o hipertrofie a glandelor mucoase (a) și granulare (b). H-Sirius red. 100 \times . (original).

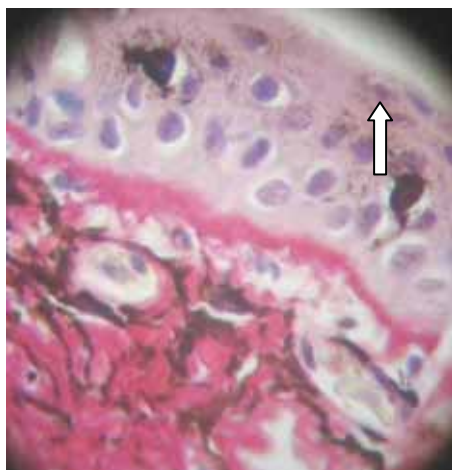

Figure 2. Epidermis of *Rana ridibunda* PALLAS 1771 showing picnotic nuclei in hornified cells (arrow). H-Sirius red. 400 \times . (originally). /

Figura 2. Epiderm de *Rana ridibunda* PALLAS 1771 ce prezintă nuclee picnotice în celulele cornoase (săgeată). H-Sirius red. 400 \times . (original).

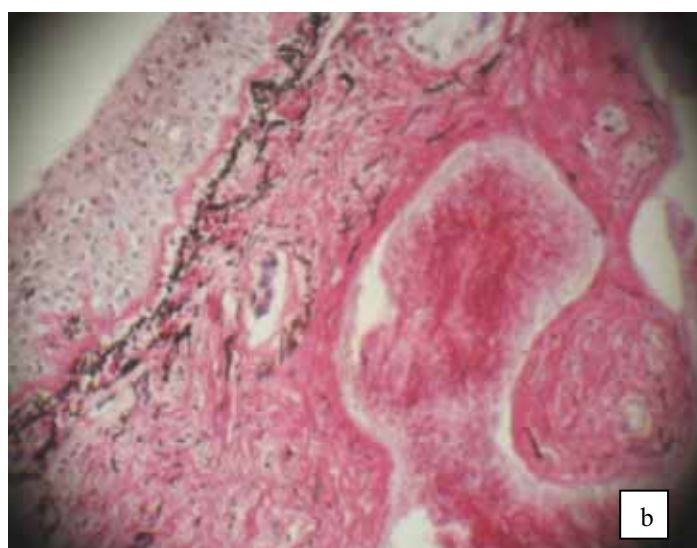
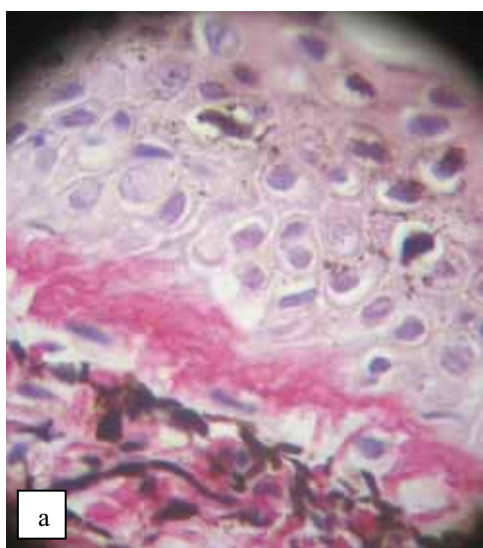


Figure 3. Skin of *Rana ridibunda* PALLAS 1771 showing a stratified epidermis (a) and a bigger dermis (b). H-Sirius red. 400 \times (a), 100 \times (b). (original). / Figura 3. Tegument de *Rana ridibunda* PALLAS 1771 care prezintă epidermul stratificat (a) și dermul îngroșat (b). H-Sirius red. 400 \times (a), 100 \times (b). (original).

