BIOANTHROPOLOGICAL DATA FOR A SKELETAL SAMPLE RETRIEVED FROM THE EXTRA MUROS NECROPOLISES OF HISTRIA

Claudia RADU[*], Norbert SZEREDAI[*], Beatrice KELEMEN[*]

Cuvinte cheie: *bioarheologie, antropologie fizică, osteoartrită, sănătate, perioadă romană târzie.*

Keywords: *bioarchaeology, physical anthropology, osteoarthritis, health, Late Roman.*

Rezumat: *Articolul prezintă rezultatele studiului antropologic realizat asupra unui lot osteologic uman provenit din cele două necropole aflate în zona Basilicii extra muros de la Histria. Scopul analizei macroscopice a fost identificarea unor aspecte legate de starea de sănătate și calitatea vieții pentru indivizii studiați. În urma determinării sexului și a vârstei la deces, pentru fiecare schelet s-a analizat prezența osteoartritei, inflamației subperiostale, patologiilor dentare, hiperostozei porotice, precum și a traumelor și fracturilor. Lotul este compus din 7 indivizi, la care se adaugă un craniu și o mandibulă de la doi indivizi diferiți. Dintre cele 7 schelete, pe baza morfologiei elementelor de diagnostic, 2 provin de la indivizi de sex feminin, 4 de la indivizi de sex masculin, iar unul de la un copil. Materialul osteologic este bine reprezentat și conservat, ceea ce a permis identificarea unor aspecte patologice cum ar fi hiperostoza scheletală*

---

[*] Claudia RADU: Molecular Biology Center, Interdisciplinary Research Institute of Bio-Nano Sciences, Babeș-Bolyai University, Cluj-Napoca, Romania.

[*] Norbert SZEREDAI: Faculty of History and Philosophy, Babeș-Bolyai University, Cluj-Napoca, Romania.

[*] Beatrice KELEMEN: Faculty of Biology and Geology, Babeș-Bolyai University, Cluj-Napoca, Romania.

Claudia Radu acknowledges that this paper is a result of a doctoral research made possible by the financial support of the Sectoral Operational Programme for Human Resources Development 2007-2013, co-financed by the European Social Fund, under the project POSDRU/187/1.5/S/155383 - "Quality, excellence, transnational mobility in doctoral research". This study was supported by funding from the project Genetic Evolution: New Evidences for the Study of Interconnected Structures (GENESIS). A Biomolecular Journey around the Carpathians from Ancient to Medieval Times (CNCSIS UEFISCDI_PNII_PCCA_1153/2011).

idiopatică difuză, nodulii lui Schmorl, osteom, sau un canin impactat.

Abstract: *We present the findings derived from the osteological analysis carried out over a human skeletal sample retrieved from the two extra muros necropolises of Histria. The study was aimed at inferring the health status and quality of life indicators based on macroscopic analysis. Following sex and age-at-death estimations, each skeleton was assessed with regard to osteoarthritis, periosteal inflammation, dental disease, porotic hyperostosis, and the presence of trauma and fractures. The sample is composed of 7 individuals, along with one unlabelled skull and one unlabelled mandible from two different individuals. Out of the 7 skeletons, the morphology of the diagnostic elements suggested 2 were women, 4 were men, and one was a child. The material displays a good degree of preservation, which has allowed for the identification of several pathological features, including Diffuse Idiopathic Skeletal Hyperostosis, Schmorl's nodes, button osteoma, and an impacted canine.*

Introduction

The skeletal sample comprises the individuals discovered in 6 individual graves (M1/08, M2/08, M3/08, M4/08, M6/10 and M20/10), a partial skeleton, a skull, and a mandible. The archaeological context is discussed in this volume in a separate article, so it will not be discussed here. The material displays a general good degree of preservation, which allowed us to observe several interesting pathological changes. At first, we will enumerate the methods used in the course of the analysis, followed by a detailed description of each individual. Finally, the anthropological and paleopathological findings are discussed.

Material and methods

For adult individuals, age at death was determined using the morphology of the sternal rib ends[1], pubic symphysis[2], auricular surface[3], along with the synostosis of the cranial sutures and dental wear[4]. For non-adult individuals, age at death was approximated based on dental eruption, measurements of the long bones, and degree of epiphyseal fusion[5].

Sex was determined using cranial (nuchal crest, petrous pyramid, supraorbital margin, glabella, mental eminence) and pelvic (subpubic concavity, subpubic angle, ischiopubic ramus, ventral arch, the great sciatic notch) morphology[6].

Stature was calculated using the formulae derived by Pearson[7], Trotter and Gleser[8], Bach (1965) and Breitinger (1937)[9]. Nevertheless, if we take into consideration the reference population on which these formulae were derived, we consider that the most correct results would be obtained by using the equations

[1] IȘCAN *et alii* 1984.
[2] BUIKSTRA & UBELAKER 1994; STECKEL *et alii* 2011; MEINDL *et alii* 1985.
[3] BUIKSTRA & UBELAKER 1994; STECKEL *et alii* 2011.
[4] WHITE *et alii* 2012.
[5] SCHAEFER *et alii* 2009.
[6] BUIKSTRA & UBELAKER 1994.
[7] PEARSON 1899, p. 196.
[8] TROTTER & GLESER 1958, p. 84-85.
[9] VERCELLOTTI *et alii* 2009, p. 138.

produced by Bach for female individuals and Breitinger for male individuals. Where these formulae could not be used, we opted for the equations derived by Trotter and Gleser (1958).

Pathological changes were analysed following the guidelines from Ortner[10], Steckel *et alii*[11], Buikstra and Ubelaker[12], Aufderheide and Rodriguez-Martin[13], and Waldron[14]. In the course of the analysis, all the skeletons were screened for the presence of degenerative joint disease, periosteal reactions, porosity specific for *cribra orbitalia* and porotic hyperostosis, and Schmorl's nodes. With regard to osteoarthritis, we observed the following skeletal elements: temporomandibular joint, glenoid cavity, proximal and distal humerus, proximal and distal radius, proximal and distal ulna, the bones of the hands, acetabular cavity, proximal and distal femur, proximal and distal tibia, proximal and distal fibula, the bones of the feet, and the vertebrae (the cervical, thoracic, and lumbar segments). For the identification of periosteal reactions, we observed the following long bones: clavicle, humerus, radius, ulna, femur, tibia and fibula.

Dental inventory and pathology was done using the protocols proposed by Buikstra and Ubelaker[15] and Steckel *et alii*[16].

Trauma and fractures were analysed using the methods described by Lovell[17] and Buikstra and Ubelaker[18].

Results

Grave M1/08

The skeleton displays a good degree of representation (75-100%). Based on the morphology of the cranial and pelvic elements, the skeleton belongs to a female individual. Age at death was determined between 33 and 46 years of age, result obtained from the observation of the sternal rib ends and pubic symphysis. Stature was calculated using Bach's formulae for the femur, which measures 403 mm. The result is 159.6 cm.

In what concerns the dentition, this individual had 32 erupted teeth, of which only 19 were present for observation and one was lost *ante mortem*. Dental caries were noted on two teeth. Moreover, four dental abscesses were present, both at the level of the mandible and maxillary. Dental calculus and periodontitis were of moderate degrees. Linear enamel hypoplasia was not present on the maxillary incisors and canines; unfortunately, the mandibular counterparts were not available for observation. Molar wear is strong and extended. Furthermore, both the incisors and the canines exhibit strong, abnormal, labial wear.

Degenerative joint disease is also very strong and affects a high number of articulations. Out of the 34 elements observed, 25 display degenerative changes.

[10] ORTNER 2003.
[11] STECKEL *et alii* 2011.
[12] BUIKSTRA & UBELAKER 1994.
[13] AUFDERHEIDE & RODRIGUEZ-MARTIN 1998.
[14] WALDRON 2009.
[15] BUIKSTRA & UBELAKER 1994.
[16] STECKEL *et alii* 2011.
[17] LOVELL 1997.
[18] BUIKSTRA & UBELAKER 1994.

The most affected elements are the bones of the right hand, the right distal femur, the right proximal tibia, the bones of the right foot and the left distal femur. These present advanced deformation and osteophytes with great dimensions. Osteoarthritis affects 16 vertebrae. The second cervical vertebra displays the strongest changes, with eburnation (Fig. 1). Moreover, several thoracic and lumbar vertebrae exhibit destructive changes at the level of the vertebral plateau and Schmorl's nodes.

Pathological new bone formation was observed on the diaphysis of both tibiae. No porosity was noted on the bones of the skull. On the right tibia, proximally, on the posterior surface, there is a large lytic lesion (Fig. 2).

Grave M2/08

The skeleton is well represented. Based on the observation of the cranial and pelvic elements, sex was attributed to a male individual. Age at death was determined between 33 and 45 years of age, as determined from the morphology of the sternal rib ends, pubic symphysis and auricular surface. Stature was calculated using Breitinger's equation for the femur, which measures 467 mm; the result is 171.13 cm.

The individual had 30 erupted teeth, of which 10 were lost *ante mortem* and 12 were available for analysis. There are no dental abscesses, but four teeth are affected by caries. Slight dental calculus and periodontitis can be seen on both the maxillary and mandible. Linear enamel hypoplasia was observed only on the mandibular canines. Molar wear varies from moderate to severe.

Degenerative joint disease was observed on a number of 31 skeletal elements out of the 34 described above (see the Methods section). Thus, 91% of the observed elements are affected.

Periosteal new bone formation was noted on 5 long bones out of 14 analysed elements. The former include both femora, both tibiae, and the left fibula.

Although *cribra orbitalia* was not present on either orbital surface, on the cranial vault we could see porosity indicative for porotic hyperostosis.

The vertebral column displays changes specific for what is called Diffuse Idiopathic Skeletal Hyperostosis (DISH) (Fig. 3). 11 vertebrae (thoracic, lumbar and sacral) are fused by bony bridges which do not affect the intervertebral space. Schmorl's nodes were identified on 7 vertebrae, mostly from the thoracic segment of the spine. Severe osteoarthritis is present at the level of the entire spine, affecting for example 6 out of the 7 cervical vertebrae. In the case of 13 vertebrae, the vertebral plateau exhibits pathological changes.

On a fragmentary rib from the left side we identified a healed oblique fracture, with a bony callus measuring 5.25 mm.

Grave M3/08

The skeleton belongs to a male individual, as determined from the cranial and pelvic elements. Age at death was estimated between 33 and 45 years of age based on the morphology of the sternal rib ends and auricular surface. Stature was calculated to be 166.03 mm, result obtained by using Breitinger's formula for the femur, which measures 436 mm.

During life-time, the individual had a number of 31 teeth, of which 19 are available for analysis and 8 were lost *ante mortem*. The right maxillary canine is not present at its normal site, but has erupted in the maxillary body, at the left of the anterior nasal spine (Fig. 4). We identified only one abscess, on the mandibular body. One tooth presents a carious lesion. Dental calculus and periostitis are slight. Moderate enamel hypoplasia was identified on the mandibular and maxillary incisors and canines. Molar wear could be analysed only for three molars, in which case dental wear was strong.

Out of 14 available joint elements, 6 display degenerative changes. No periosteal reactions were noted on either long bone. On both orbital roofs we could see healed porosity.

Schmorl's nodes are present on 7 thoracic vertebrae. These are also affected by osteoarthritis and 3 of them present destructive changes on the vertebral plateau.

One fragmentary rib from the left side exhibits an oblique fracture in a healed state, with a bony callus measuring 14.77 mm.

Grave M4/08

Apart from the bones belonging to the main adult individual, we also identified two tibiae from a child who died at approximately 3 months postpartum.

The adult skeleton is well preserved. Based on the cranial and pelvic diagnostic elements, we concluded that it belongs to a female individual with an age at death between 24 and 35 years. Stature was calculated using the formula derived by Bach for the femur, which measures 436 mm. The result is 163.93 cm.

The dental inventory for this individual is distinct: the left lateral maxillary incisor is represented only by a small tooth bud poorly visible in an enclosed socket; the third molar did not erupt neither on the maxillary or the mandible; the second molar has also not erupted on the right side of the mandible. Therefore the following dental scheme was produced: right mandible 2121; left mandible 2122; right maxillary 2122; left maxillary 1122. Consequently, the individual had in the course of its life-time 26 erupted teeth, of which one was lost *ante mortem* and 18 are available for observation. None of the teeth displays dental caries or abscesses. Dental calculus and periodontitis range from moderate to severe levels. No hypoplastic defects were observed. Molar wear is moderate, with the exception of the right second mandibular molar which exhibits no wear at all, probably due to the fact that its counterpart is missing.

Degenerative joint disease was seen on 21 joint elements out of 31 present for observation. The most affected were the right distal femur and right proximal tibia. These exhibit osteophytes with great dimensions and severe changes in the shape of the joint.

Moreover, on the right tibia, under the tibial plateau, laterally, we identified a cavity measuring 12.11 x 9.83 x 8.15 mm. The edges of the cavity and the morphology of the bone surrounding it suggest that the process of osseous destruction and remodelling was active at the time of death. On the ventral side of the pubis, on the insertion site of the posterior ligament, there is also a large

cavity with a diameter of 7.66 mm and 7.21 mm deep. This lesion is nevertheless in a healed state.

Out of the 13 long bones available for analysis, only the right tibia displayed signs of periosteal inflammation. The proximal half of the tibia is considerably swelled. The perimeter of the bone at the site of the tibial foramen measures 103 mm, whereas for the left tibia, at the same site, the perimeter is only 84 mm (Fig. 5).

No porosity at the level of the skull was noted. Neither was the presence of Schmorl's nodes. Osteoarthritis affected the majority of the thoracic vertebrae (*n*=11). We identified two vertebrae with destruction on the vertebral plateau. Furthermore, the intervertebral space between the last two thoracic vertebrae was lost, leading to ankylosis (Fig. 6).

On the right parietal bone we noted the presence of a circular trauma (10 x 6 mm) sustained with a blunt object. The lesion is healed with no signs of infection.

On the frontal bone we could see a small sized button osteoma, which is a benign tumor[19] (Fig. 7).

Grave M6/10

The skeleton is moderately preserved. It belongs to a male, as determined from the cranial and pelvic elements. Age at death was approximated between 43 and 55 years using the morphology of the sternal rib ends and auricular surface. Stature was calculated following the formula derived by Trotter and Gleser (1958) for humerus, which in this case measures 313 mm. The result is a height of 166.85 cm.

Dental analysis could not be performed due to the fact that the facial skeleton, including all the teeth, are missing.

Degenerative joint changes were identified on 5 elements out of 17 available for observation. The most affected elements are those of the right hand. On both tibiae we could see pathological new bone formation. The individual also displays on the cranial vault porotic hyperostosis. The vertebrae are poorly preserved and therefore could not be processed for analysis. A rib fragment from the left side presents a healed oblique fracture.

Grave 20/10

Apart from the bones of the main individual, we identified a mandible belonging to an adult.

The skeleton is moderately preserved. It belongs to a non-adult with an age at death between 6 and 18 months postpartum, as determined from the dental eruption and measurements of the long bones.

Four decidual teeth were preserved. On these no pathological features were seen. Although on the postcranial elements there was no porosity or new bone formation, on the cranium there was porosity at the level of the cranial vault and orbital roofs (*cribra orbitalia*).

[19] ESHED *et alii* 2002, p. 229-230.

Unlabelled skeleton

The skeleton is poorly preserved. Following an analysis of the cranial elements (nuchal crest, supraorbital margin, petrous pyramid, glabella, mental eminence) we concluded that the skeleton belongs to a male individual. The coxal bones were not present for observation and therefore could not be assessed. The age at death for this individual was approximated between 17 and 25 years, based on the level of epiphyseal fusion and dental wear. Thus, both on the vertebrae and on the long bones the fusion lines could still be seen, which points to a minimum age limit of 18. Furthermore, dental wear is very weak; according to Brothwell's scheme[20], this level of dental wear is indicative for an age at death between 17 and 25 years. In addition, the third molar, which usually erupts at about 17 years of age, has barely erupted.

Stature was calculated using the formula derived by Trotter and Gleser (1958) for the tibia measured without the eminence, which in this case measures 333 mm. The result is 158.1 cm.

The mandible is not preserved and as a consequence for the dental analysis we could observe only the maxillary. Out of 16 tooth sockets, 10 teeth are available for analysis. There are no closed sockets indicative for teeth lost *ante mortem*, and no abscesses or dental caries. As said earlier, molar wear is barely visible.

Degenerative joint disease was not seen on either element from the 9 present for analysis. However, periosteal reactions were noted on the left tibia out of 5 preserved long bones.

Although on the orbital roofs there is no porosity suggestive for *cribra orbitalia*, the cranial vault is extensively affected, especially on the parietals and frontal bone. No pathological findings were identified on the vertebrae.

On the frontal bone, near the coronal suture, we identified a healed trauma, sustained with a blunt object. The lesion measures 12.75 x 17.14 mm.

Unlabelled skull

The skull is well preserved and based on the diagnostic elements, it belongs to a male individual. Furthermore, using the degree of cranial suture closure, the age at death was determined between 51.5 and 56.2 years. No pathological features were identified.

Unlabelled mandible

Based on the morphology of the mental eminence, we could suggest that the mandible belongs to a female, but this result has a low probability as the other diagnostic elements are missing. Dental wear points to an age at death between 25 and 35 years. Out of 16 erupted teeth, only 6 are available for analysis. No abscesses, dental caries or teeth lost *ante mortem* were identified. Dental calculus is moderate, as is molar wear. On the temporomandibular joint we could see slight degenerative changes.

[20] WHITE *et alii* 2012, 390.

Discussion

Any conclusions which could be drawn from the anthropological analysis are hindered by the small number of individuals. At this point, we can only make limited inferences with regard to the health status of these individuals.

Stature, *cribra orbitalia*, porotic hyperostosis, and linear enamel hypoplasia can be used as indicators for the health status of the individuals in the course of their childhood.

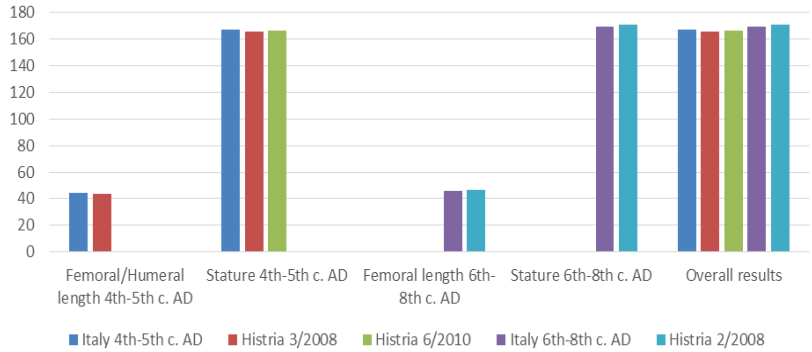

Table 1. Stature for male individuals.
The data for the Italian territory were taken from the publication of Giannecchini, Moggi-Cecchi (2008).

On the other hand, the distribution and degree of severity for degenerative joint disease can be used in order to understand, although in a limited way, the type of physical activities performed by these individuals in the course of their life-time. Furthermore, the pathological features identified at the level of each skeleton offer additional data in what concerns the life-quality levels experienced by these individuals.

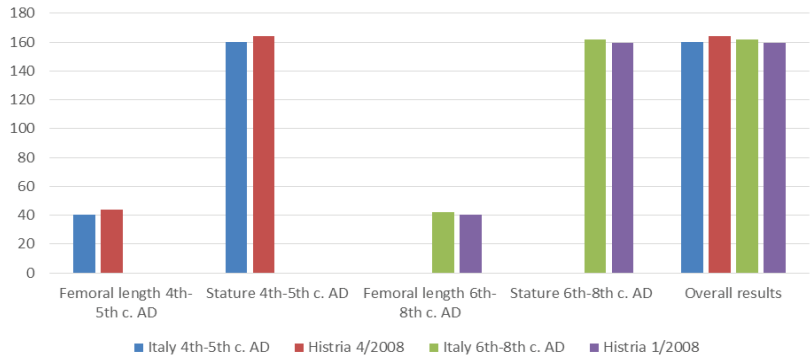

Table 2. Stature for female individuals.
The data for the Italian territory were taken from the publication of Giannecchini, Moggi-Cecchi (2008).

Grave no.	Sex	Age at death	Stature (cm)	*Cribra orbitalia*	*Cribra cranii*	LEH*	Dental calculus	Period.*	Abscesses	AMTL*	DC*
1	F	33-46	159,6	-	-	X	Severe	Moderate	4	1	2
2	M	33-45	171,13	-	X	-	Weak	Moderate	0	10	4
3	M	33-45	166,03	X	-	X	Moderate	Moderate	1	8	1
4	F	24-35	163,93	-	-	-	Severe	Severe	0	1	0
6	M	43-55	166,85	-	X	-	-	-	0	0	0
20	IND	6-18 months	/	X	X	-	-	-	0	0	0

Table. 3 - Sex, age at death, and distribution of dental pathology for the Histria sample.

**LEH – linear enamel hypoplasia; Period. – periodontitis; AMTL – antemortem tooth loss; CT – teeth with carious lesions*

The skeletons belonging to the individuals from graves M1/08 and M2/02 present with one stress indicator associated with childhood and osseous development. However, if we compare the calculated stature with the other individuals from this sample and even with the results described in other bioarchaeological studies[21], we see that the values calculated for individuals M1/08 and M2/08 are high. This could point to either a nutritional input suitable for the growth and development of the skeleton and/or to a genetic base which gave the individuals the potential for achieving a high stature. Nevertheless, the fact that they survived trough adulthood points to the fact that they were able to overcome any physical insults to which they were exposed as children.

Dental pathology is extended in the case of both individuals. These conditions (high number of teeth lost antemortem, the presence of dental calculus and periodontitis, the presence of abscesses and dental caries, strong dental wear) can be correlated with various disease complexes. Moreover, periosteal inflammation is also suggestive for an either systemic or localised infection. Therefore, dental pathology and the presence of periosteal reaction are indicative for a poor health status which probably affected the individuals in their adult years.

To support this hypothesis, we can take into consideration the distribution and frequency of joint elements affected by degenerative changes due to osteoarthritis (Fig. 8). In the case of these two individuals, 25 and 31 joint elements are affected, respectively. What's more, these pathological changes are quite strong on the vertebral column, which also exhibits Schmorl's nodes and destruction of the vertebral plateau. All of these point to a prolonged functional stress experienced by both individuals. In the case of the individual from grave M2/08, the presence of DISH is a condition that could be explored on its own in the future. Other studies have correlated this pathological feature with diseases related to alimentation like obesity and diabetes[22].

The individuals from graves M3-M 4/08, and M6/10 also display various pathological features both at the level of the dentition and of the skeleton. Skeletal indicators for nutritional and functional stress were identified. Osteoarthritis affects to the strongest degree the remains of the woman from grave M4/08, who is also the youngest from these three individuals. Moreover, vertebral ankylosis and the two lytic lesions are also pointing to severe functional stress. This particular individual does not display skeletal stress indicators like *cribra orbitalia*, porotic hyperostosis, or linear enamel hypoplasia, but the other two male individuals (from graves M3/08 and M6/10) present with lesions at the level of the skull and teeth which are indicative for nutritional deficiencies during childhood.

Finally, the non-adult from grave M20/10 exhibits lesions specific for porotic hyperostosis and *cribra orbitalia*, which supposedly represent a skeletal response to anaemia, either acquired (iron-deficiency anaemia) or genetic (sickle cell

[21] GIANNECCHINI & MOGGI-CECCHI, 2008, 289-291.
[22] JANKAUSKAS 2003, p. 289-290; OSTENDORF SMITH *et alii*, 2013, p. 15-16.

anaemia and thalassemia). The age at death of this individual is consistent with both forms of anaemia.

Conclusions

The human skeletal material presented in this paper provides data with regard to the life style and health status of 7 individuals living between the 4th and the 7th centuries AD. The extended osteoarthritic changes along with other features are pointing out the physical activities performed. Furthermore, the presence of skeletal indicators for infection and nutritional deficiencies are suggestive for an impaired health status.

BIBLIOGRAPHY

AUFDERHEIDE & RODRIGUEZ-MARTIN 1998 – A. C. Aufderheide & C. Rodriguez-Martin, *The Cambridge Encyclopedia of Human Paleopathology* (third edition), Cambridge, 1998.

BUIKSTRA & UBELAKER, 1994 – Jane E. Buikstra & Douglas H. Ubelaker (eds.), *Standards for Data Collection from Human Skeletal Remain*s. Arkansas Archaeological Survey Research Series No. 44, 1994.

ESHED *et alii* 2002 – V. Eshed, B. Latimer, C. M. Greenwald, L. M. Jellema, B. M. Rothschild, S. Wish-Baratz, I. Hershkovitz, *Button osteoma: Its Etiology and Pathophysiology*. American Journal of Physical Anthropology 118 (2002), p. 217-230.

GIANNECCHINI & MOGGI-CECCHI 2008 – M. Giannecchini & J. Moggi-Cecchi, *Stature in Archaeological Samples from Central Italy: Methodological Issues and Diachronic Changes*. American Journal of Physical Anthropology 135 (2008), p. 284- 292.

IȘCAN *et alii* 1984 – M. Y. Ișcan, S. R. Loth & R. K. Wright, *Metamorphosis at the Sternal Rib End: A New Method to Estimate Age at Death in White Males*. American Journal of Physical Anthropology 65 (1984), p. 147-156.

JANKAUSKAS 2003 – R. Jankauskas, *The Incidence of Diffuse Idiopathic Skeletal Hyperostosis and Social Status Correlations in Lithuanian Skeletal Materials*. International Journal of Osteoarchaeology 13 (2003), p. 289-293.

LOVELL 1997 – N. C. Lovell, *Trauma Analysis in Paleopathology*. Yearbook of Physical Anthropology 40 (1997), p. 139-170.

MEINDL *et alii* 1985 – R. S. Meindl, C. O. Lovejoy, R. P. Mensforth & R. A. Walker, *A Revised Method of Age Determination Using the Os Pubis With a Review and Tests of Accuracy of Other Current Methods of Pubic Symphyseal Aging*. American Journal of Physical Anthropology 68 (1985), p. 29-45.

ORTNER 2003 – D. J. Ortner, *Identification of Pathological Conditions in Human Skeletal Remains* (second edition), Academic Press, London, 2003.

OSTEONDORF SMITH *et alii* 2013 – M. Ostendorf Smith, J. R. Dorsz & T. K. Betsinger, *Diffuse Idiopathic Skeletal Hyperostosis (DISH) in pre-Columbian North America: Evidence from the eastern Tennessee River Valley*. International Journal of Paleopathology 3 (2013), p. 11-18.

PEARSON 1899 – K. Pearson, *Mathematical contributions to the theory of evolution. V. On the reconstruction of the stature of prehistoric races*. Philosophical Transactions of the Royal Society London 192 (1899), p. 169-244.

SCHAEFER *et alii* 2009 – M. Schaefer, S. Black & L. Scheuer, *Juvenile Osteology. A Laboratory and Field Manual*, Academic Press, London, 2009.

STECKEL *et alii* 2011 – R. H. Steckel, C. S. Larsen, P. W. Sciulli, P. L. Walker, Data Collection Codebook for the Global History of Health Project. (http://gloval.sbs.ohio-state.edu/new_docs/Codebook-01-24-11-em.pdf)

TROTTER & GLESER 1958 – M. Trotter & G. C. Gleser, *A re-evaluation of estimation of stature based on measurements of stature taken during life and of long bones after death*. American Journal of Physical Anthropology 16 (1958), p. 79–123.

VERCELLOTI *et alii* 2009 – G. Vercelloti, A. M. Agnew, H. M. Justus & P. W. Sciulli, *Stature Estimation in an Early Medieval (XI-XII c.) Polish Population: Testing the Accuracy of Regression Equations in a Bioarchaeological Sample*. American Journal of Physical Anthropology 140 (2009), p. 135-142.

WALDRON 2009 – T. Waldron, *Palaeopathology*, Cambridge, 2009.

WHITE *et alii* 2012 – T. D. White, M. T. Black & P. A. Folkens, *Human Osteology* (third edition), Oxford, 2012.

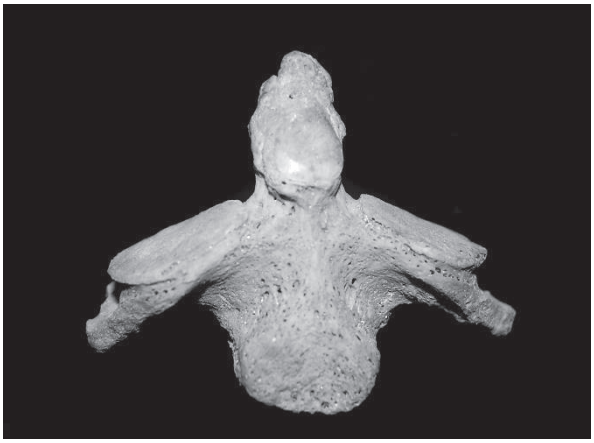

Fig. 1 - The second cervical vertebra from individual M1/2008 showing eburnation on the odontoid process.

Fig. 2 - Posterior surface of the right tibia from individual M1/2008 showing lipping of the joint margins and a lytic lesion.

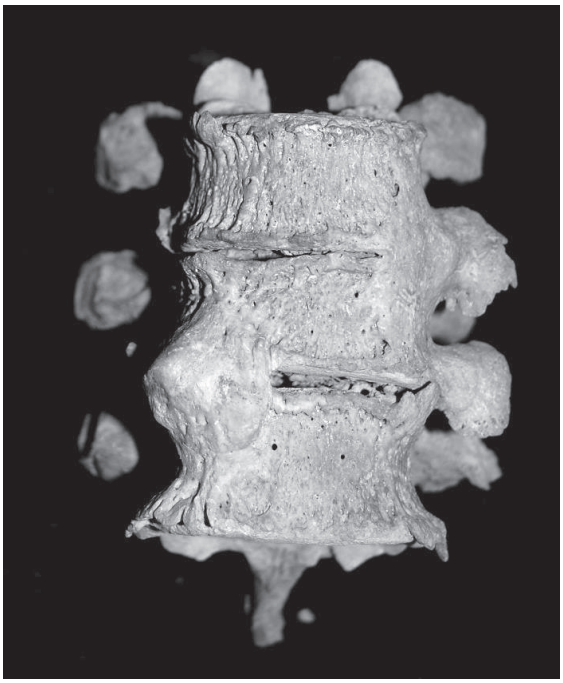

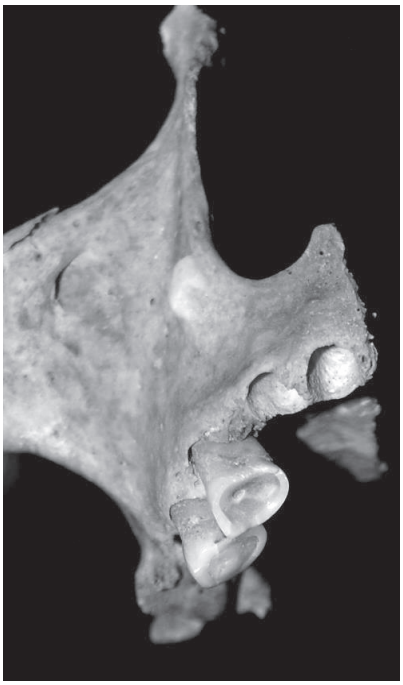

Fig. 3 (left) - A segment from the thoracic spine showing bony bridges characteristic for DISH from individual M2/2008.

Fig. 4 (right) - The left half of the maxillary body with the canine erupted next to the canine fossa from individual M3/2008.

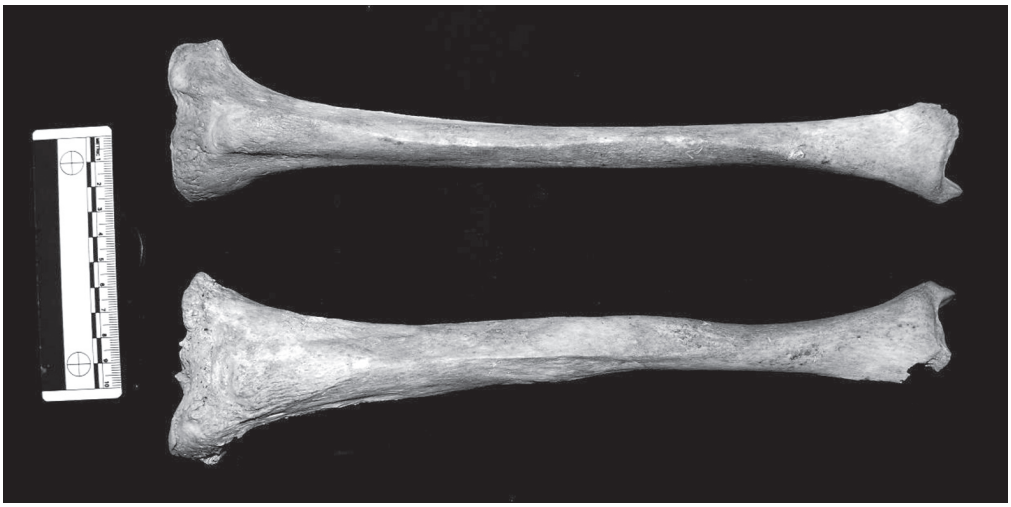

Fig. 5 - Tibiae belonging to the individual M4/2008. The right tibia shows an enlargement of the diaphysis as compared to its left counterpart.

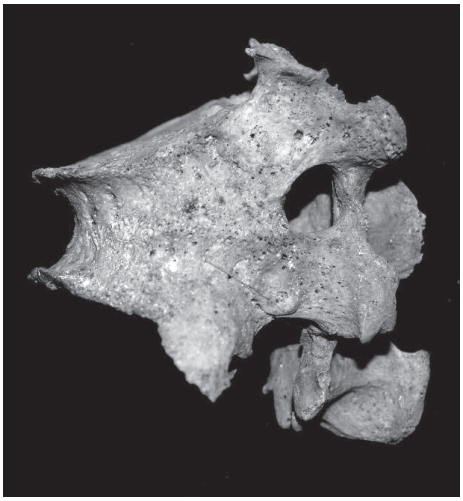



Fig. 6 (left) - Vertebral ankylosis (individual 04/2008).
Fig. 7 (right) - Button osteoma on the frontal bone (individual 04/2008).

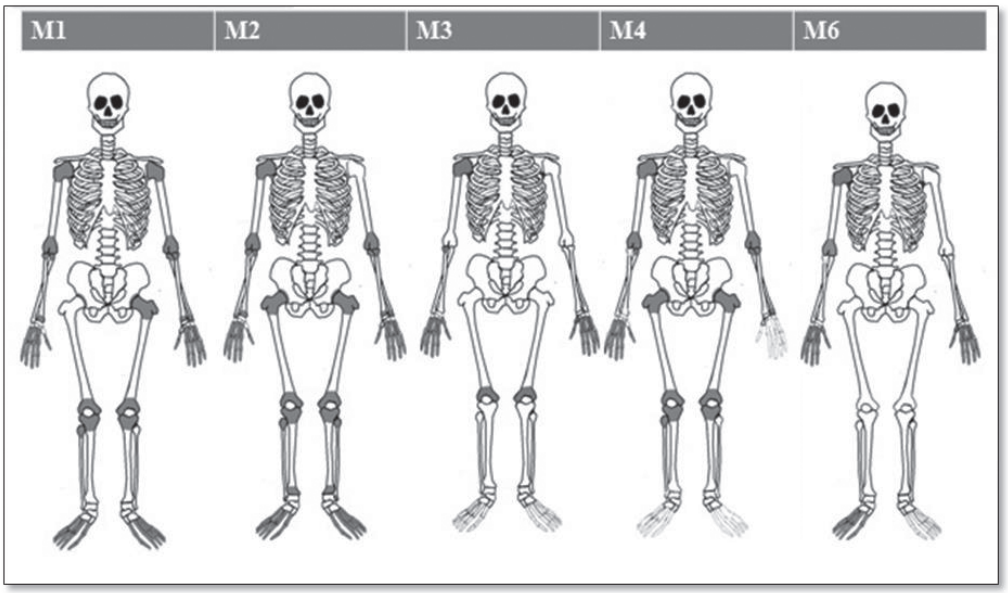

Fig. 8 - Distribution of osteoarthritis (in grey) for the analyzed sample.